18.5% versus 0% complications

Iulian Filipov1, Irina Otelea2, Cristian Rotaru3, Mircea Baldea4, Davide Farronato5 ,Lucian Chirila6

1 DDS, Opera Dental, Private Practice, Minec , Romania
2 DDS, Opera Dental, Private Practice, Minec , Romania
3 DDS, Stomproced Private Practice, Minec , Romania
4 Resident, Medical University of Bucharest, School of Maxillofacial Surgery, Minec, Romania
5Assistant Professor,University of Insubria, Department of Surgical and Morphological Sciences, Italy
6Assistant Professor, Medical University of Bucharest, Department of Maxillofacial Surgery, Romania

Object

Hard and soft tissue management during implant placement is a challenge for clinician especially in non contained bone defect. The purpose of this study was to evaluate the rate of complication associated with use of titanium mesh with or without soft tissue grafting.

Materials and Methods

Twenty-seven patients with atrophic ridges received lateral ridge augmentations with particulate grafts placed around implants and protected with i-Gen membrane. 12 of the 27 treated sites were in the anterior esthetic zone. All data were then inserted in a statistical software (SPSS 21, IBM) and processed.

Results

The treated defects were successfully regenerated.The three-dimensional contour of the compromised alveolus was re-established using titanium mesh with rigid screw fixation by the means of implant cover screw or healing abutments. In 81.5 % (22) implants, healing was uneventful, in 14.8 % (4) implants there was a dehiscence and in 3.7 % (1) the healing was compromised by dehiscence and infection. In this case, both the grafting material and the implant were removed. In all the other cases , implants were prosthetically restored . Spearman Correlation (2-tailed) reveled that results were observed to be statistically significative.

Conclusions

The findings from the present study indicate the importance of soft tissue grafting in cases where titanium mesh is used as a scaffold. Furthermore, exposure of titanium mesh during healing does not necessarily compromise the final treatment outcome. Within the limit of this restricted study, the use of titanium mesh at the time of implant placement is a reliable option of bone grafting.

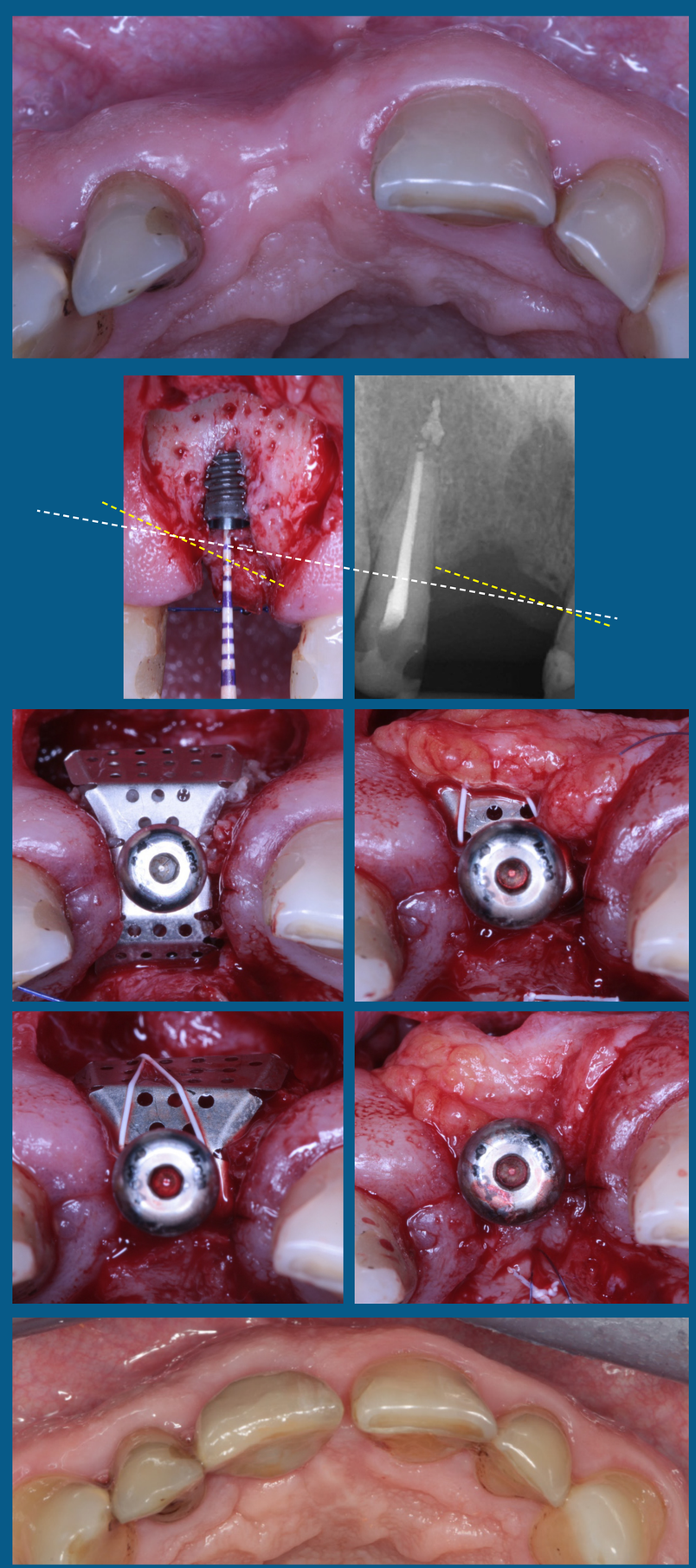

			Complication	Soft tissue grafting
Spearman's rho	Complication	Correlation Coefficient	1.000	.484*
		Sig. (2-tailed)	.	.010
		N	27	27
	Soft tissue grafting	Correlation Coefficient	.484*	1.000
		Sig. (2-tailed)	.010	.
		N	27	27

*. Correlation is significant at the 0.05 level (2-tailed).

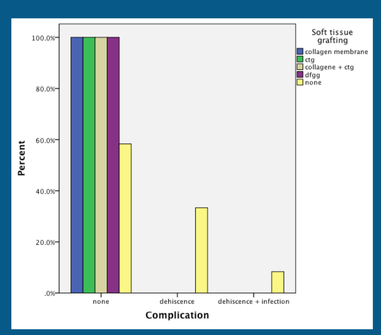

References

1. Proussaefs P, Lozada J, Kleinman A, et al: The use of titanium mesh in conjunction with autogenous bone graft and inorganic bovine bone mineral (Bio-Oss) for localized alveolar ridge aug- mentation: A human study. Int J Periodontics Restorative Dent 23:185, 2003
2. Ikuya Miyamoto; Katsuyuki Funaki; Kensuke Yamauchi; Takashi Kodama; Tetsu Takahashi ridge reconstruction with
titanium mesh and autogenous particulate bone graft: computed tomography-based evaluations of augmented bone quality
and quantity Clinical Implant Dentistry and Related Research. 2012 . 10.1111/j.1708-8208.2009.0025
3. Giuseppe Corinaldesi; Milena Fini; Nicolò N Aldini; Roberto
Giardino; Claudio Marchetti ridge augmentation with titanium mesh and
a combination of autogenous bone and anorganic bovine bone: a 2-year
prospective study Journal of periodontology. 2008 . 10.1902/jop.
2008.080061 Pieri;
4. B Assenza; M Piattelli; A Scarano; G Lezzi; G Petrone; A Piattelli
Localized ridge augmentation using titanium micromesh
The Journal of oral implantology.
2001 . 10.1563/1548-1336(2001)027<0287:LRAUTM>2.3.CO;2